



Cynthia R. L. Webster, DVM, Diplomate ACVIM, and Johanna C. Cooper, DVM, Tufts University

Diagnostic Utility of Bile Acid Determination in Dogs

P Profile

Definition

- Ancillary biochemical tests that reflect hepatobiliary function are often required in clinical practice.
- Since clinical signs are often nonspecific, first clue that primary disease exists often comes from an initial database that reveals increases in serum hepatobiliary enzymes (ALT, AST, GGT, and ALP).
- These serum enzymes are useful in screening for hepatobiliary disease because they have a high sensitivity (ie, likelihood of a positive or abnormal test result when hepatobiliary disease is present) but lack specificity (ie, likelihood of obtaining a negative or normal test result when hepatobiliary disease is not present). Increases can reflect induction from glucocorticoids or anticonvulsants (ALT, GGT, and ALP) or can originate from nonhepatic tissues, such as muscle (ALT, AST), red blood cells (AST), or bone (ALP). In addition, because of the liver's high blood flow and role in intermediary metabolism, increases may reflect primary disease in other organ systems, especially the gastrointestinal tract.
- Serum hepatobiliary enzymes cannot be used to assess the functional capacity of the liver. Hepatobiliary function must be assessed by assaying for substances that are synthesized or excreted exclusively by the liver.
- A sensitive hepatobiliary function test in the dog is measurement of total serum bile acids (TSBA).

Systems

Bile acids are useful in the diagnosis of hepatobiliary dysfunction associated with reduced hepatic mass or hepatoportal perfusion abnormalities, such as congenital portosystemic shunts (CPSS), multiple acquired portosystemic shunts (MAPSS), primary hypoplasia of the portal vein (PHPV) without portal hypertension (previously termed microvascular dysplasia),¹ PHPV with portal hypertension (also called noncirrhotic portal hypertension),¹ and hepatoarteriovenous fistula.

Dx Diagnosis

Diagnostic Utility of Serum Bile Acids

The prevalence of hepatobiliary disease in dogs is unknown; however, elevated hepatobiliary enzymes are common. In a study of dogs with a variety of ailments, serum ALP or ALT were elevated in 32% and 47% of cases, respectively.² Another study found elevated ALP, ALT, GGT, or AST in 39%, 17%, 19%, and 11% of cases, respectively.³ CPSS account for 22% to 32% of canine congenital vascular defects, and one retrospective study found CPSS in 0.18% of dogs.⁴ Several common breeds are predisposed to inflammatory/fibrotic hepatopathies (Table 1) and portovascular anomalies (PVAs) (Table 2). Thus, a sensitive test of hepatobiliary function or hepatoportal perfusion in private practice is required.

Bile Acids Testing

Method

- TSBA are routinely measured by a direct enzymatic spectrometric method.
- Patients undergoing TSBA testing should be fasted for 12 hours, after which a baseline serum sample is obtained.
- Postprandial TSBA are obtained 2 hours after feeding 2 teaspoons (if under 10 lb) to 2 tablespoons (larger patients) of a maintenance canned diet. A large quantity of food is not necessary to initiate gallbladder contraction and may increase postprandial lipemia.

Sample Submission

- Samples must not be lipemic (lipemia artifactually increases TSBA) or hemolyzed (moderate to marked hemolysis artifactually decreases TSBA).

Sensitivity and Specificity of TSBA

- Parenchymal hepatobiliary disease:
 - For the diagnosis of hepatobiliary disease, a fasting TSBA value > 15 $\mu\text{mol/L}$ has a sensitivity and specificity of 63% and 95%, respectively. A further increase in the fasting TSBA cutoff to > 20 $\mu\text{mol/L}$ results in 100% specificity.⁵
 - A postprandial TSBA value > 30 $\mu\text{mol/L}$ has a sensitivity and specificity of 71% and 100%, respectively, for hepatobiliary disease.⁵
- Portosystemic shunts (PSS) (CPSS and acquired shunting):

continues

Table 1. Breeds Predisposed to Inflammatory Hepatopathies

American cocker spaniel
Bedlington terrier
Dalmatian
Doberman pinscher
English cocker spaniel
Labrador retriever
Skye terrier
West Highland white terrier

- For the detection of PSS, a fasting TSBA value > 8 µmol/L has a sensitivity and specificity of 89% and 68%, respectively. Further increase in fasting TSBA to > 20 µmol/L increases the specificity to 81%.⁵
- A postprandial TSBA value > 30 µmol/L has a sensitivity approaching 100% for the detection of vascular disease.⁵
- The high sensitivity of postprandial TSBA for the diagnosis of PSS makes TSBA a useful screening test for PSS.

Interpretation of Results

- Fasting TSBA:
 - 20% of dogs may have greater fasting TSBA than postprandial TSBA because of spontaneous gallbladder contraction or differences in gastric emptying rates, cholecystokinin release, response to cholecystokinin, or altered intestinal transit time. However, both values are usually within the reference range, indicating normalcy.
- Postprandial TSBA:
 - Diagnostic efficacy is nearly identical to that of fasting TSBA for most disorders,

Table 2. Portovascular Anomalies and Associated Breed Predilection

Vascular Anomaly	Breed Predilection
<i>Congenital portosystemic shunts (CPSS)</i>	
Extrahepatic	Yorkshire terrier, Cairn terrier, pug, Maltese, dachshund, miniature Schnauzer, Havanese, dandie dinmont terrier
Intrahepatic	Irish wolfhound, Old English sheepdog, Samoyed, golden retriever, Labrador retriever, Australian cattle dog
<i>Primary hypoplasia of the portal vein (PHPV)</i>	
PHPV without portal hypertension	Yorkshire terrier, Cairn terrier, miniature dachshund, Shih Tzu, toy poodle
PHPV with portal hypertension	Rottweiler, cocker spaniel, Doberman pinscher
Portal vein atresia	None
<i>Arteriovenous fistula</i>	None
<i>Multiple acquired portosystemic shunts (MAPSS)</i>	Breed predilection may be evident based on primary cause

except vascular anomalies (CPSS and acquired shunting).

- Inaccurate postprandial TSBA may occur because of failure of cholecystokinin release or gallbladder contraction due to physiologic variability or because amount of test meal is insufficient.
- Theoretically, decreased postprandial TSBA results may occur in cases of severe ileal disease secondary to decreased bile acid reabsorption, but in reality this rarely occurs.
- 2 hours only approximates the optimal time for postprandial sample collection.
- Maltese dogs may have increased postprandial TSBA in the absence of congenital portovascular anomalies for unknown reasons; however, results of the ammonia tolerance test will be normal.⁶

- When monitoring disease progression or response to therapy using sequential TSBA, a marked decrease or return to normal can be used to indicate improvement or resolution.

Limitations of Bile Acids Testing

- TSBA values cannot be used to discriminate one hepatobiliary disease from another.
- TSBA values cannot predict the severity of the histologic lesion or the degree of portosystemic shunting.
- TSBA testing has no added diagnostic value when hyperbilirubinemia is present.
- Ursodeoxycholic acid treatment (15 mg/kg orally given with food) increased the TSBA in 6 of 14 clinically normal dogs (25–75 µmol/L) and increased urine bile acids in 1 of 14 dogs.⁷ While no studies

ALP = alkaline phosphatase, ALT = alanine aminotransferase, AST = aspartate aminotransferase, CPSS = congenital portosystemic shunt, GGT = α-glutamyltransferase, MAPSS = multiple acquired portosystemic shunts, PHPV = primary hypoplasia of the portal vein, PVA = portovascular anomalies, TSBA = total serum bile acids

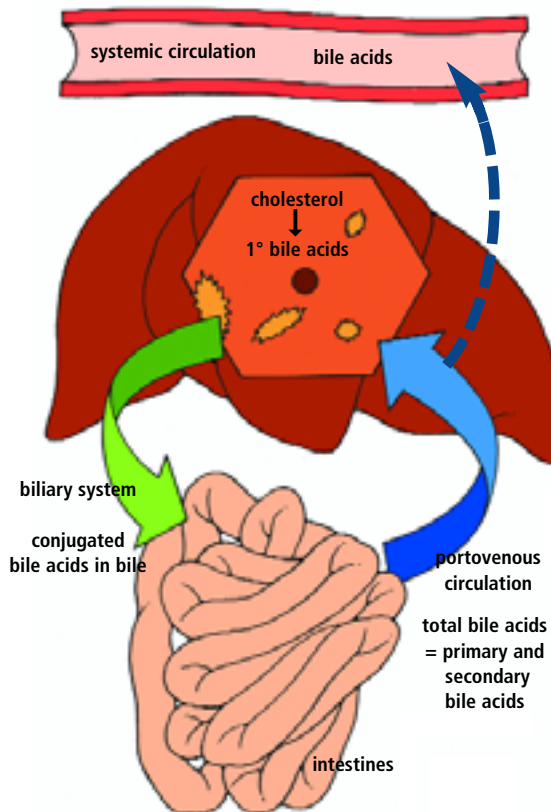
have been conducted on the use of TSBA testing as a monitoring tool for dogs receiving ursodeoxycholic acid for the treatment of liver disease, similar but possibly more pronounced effects are possibly in such dogs.

Further Diagnostic Evaluation

(Warranted by elevated TSBA)

- A test that may have diagnostic value similar to that of TSBA in assessing hepatobiliary function is **blood ammonia**. A recent study indicated that fasting plasma ammonia concentrations were more sensitive and specific for the detection of portosystemic shunting than fasting TSBA.⁸ However, another study found that postprandial ammonia tolerance tests had poor sensitivity for detecting liver disease in the absence of PSS.⁹ These results are consistent with those of previous clinical studies and dog models of liver disease without acquired shunting.¹⁰ The diagnostic utility of blood ammonia is limited by the need for meticulous sample handling, including avoidance of hemolysis, use of cold heparinized tubes, transfer on ice, and refrigerated centrifugation and assay.
- Fasting TSBA > 15 µmol/L or postprandial TSBA > 30 µmol/L warrant further evaluation (see **Diagnostic Tree**, page 32).
- Once an elevation in TSBA is found, **abdominal ultrasonography** should be pursued.
- Ultrasonography may depict a PVA, such as CPSS or MAPSS.
- Portal vasculature:
 - Visualization of a shunt, with the following test characteristics: sensitivity and specificity of 97% and 90%, respectively, for a single extrahepatic CPSS,¹¹ and 100% sensitivity and specificity for a single intrahepatic CPSS.¹¹
 - Turbulence in the caudal vena cava, with positive predictive value of 91% and negative predictive value of 84% for the presence of a PSS terminating

Normal Circulatory Routes of Bile Acids

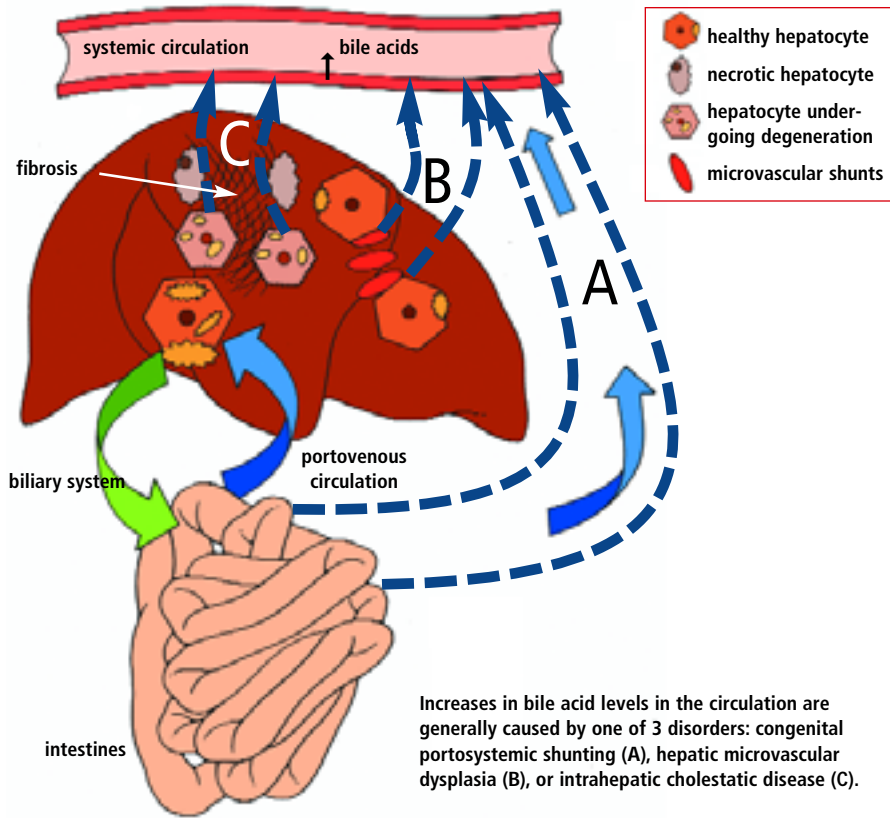


The primary bile acids are synthesized from cholesterol, conjugated to glycine or taurine, secreted into the canaliculi, and transported to the intestines by the biliary system. Intestinal bacteria metabolize some of the primary bile acids to form secondary bile acids. Conjugated bile acids are efficiently absorbed by the ileum into the portovenous circulation and transported to the liver, where the majority are efficiently taken up by hepatocytes and reexcreted into bile. The integrity of the enterohepatic circulation for bile acids results in a very effective recycling process.

- into the caudal vena cava.¹¹
- Portal vein–aorta ratio ≥ 0.65 is consistent with an extrahepatic CPSS, or a PHPV and MAPSS.¹¹
- Portal vein/caudal vena cava ratio ≥ 0.75 rules out an extrahepatic CPSS in 100% of cases.¹¹
- Reduced or reversed flow in the portal vein is seen in 100% of cases of MAPSS (< 10 cm/sec) secondary to portal hypertension.¹¹
- Visualization of a hepatic arteriovenous fistula (HAV).
- Accurate evaluation of portal vasculature is highly operator dependent.
- When vascular anomaly is not identified on ultrasonography, other ultrasonographic findings may suggest a portovascular disorder:
 - Microhepatica
 - Hypovascular liver
- Nodular liver: cirrhosis with secondary MAPSS
- Renomegaly
- Uroliths: ammonia urate stones seen most commonly with CPSS, more rarely with PHPV
- Abdominal effusion: MAPSS, HAV
- Abdominal ultrasonographic findings may suggest hepatic parenchymal disease:
 - Focal or multifocal lesions: hepatobiliary neoplasia, nodular hyperplasia, metastatic disease, abscess
 - Hyperechoic liver: lymphosarcoma, steroid hepatopathy, hepatic lipidosis
 - Hypoechoic liver: lymphosarcoma, acute hepatitis
 - A normal liver on abdominal ultrasonography, however, does not rule out primary liver disease.
- If ultrasonographic evaluation of the

continues

Abnormal Routes of Bile Acids Through the Circulatory System



suspected disease, liver size, presence of ascites, equipment available, and experience of surgeon.

- In breeds with known inflammatory hepatopathies (Table 1), additional samples may be submitted for special stains and quantitative analysis for copper and iron.
- Since hepatobiliary disease may predispose to hepatobiliary infections, **liver tissue and bile cultures** may be warranted (aerobic and anaerobic).

Follow-up

Patient Monitoring Hepatobiliary disease

- Improvement indicated by return of TSBA to normal
- Serial monitoring of serum hepatobiliary enzymes, bilirubin, albumin, cholesterol, glucose, and blood urea nitrogen
- Periodic physical examination to identify weight loss, muscle wasting, and ascites (development of portal hypertension)
- Monitoring for evidence of gastric ulceration or signs of hepatic encephalopathy

hepatic parenchyma is nondiagnostic or no shunting vessel is identified, further diagnostics depend on the suspected underlying disorder (vascular anomaly or hepatobiliary disease).

- If a vascular anomaly (CPSS) is suspected (younger dog of predisposed breed) but not confirmed on ultrasonography, consider diagnostic imaging such as **rectal or transplenic scintigraphy**.
 - Normal findings on rectal scintigraphy or transplenic portography are most consistent with PHPV.
 - Abnormalities on rectal scintigraphy or transplenic portography are consistent with CPSS or MAPSS.
 - Transplenic portography can distinguish between CPSS and MAPSS, while rectal

scintigraphy cannot.

- If an underlying hepatobiliary disease is suspected, **hepatic biopsy** should be pursued if coagulation tests are normal.
- Hepatic biopsy should also be considered when MAPSS are identified to determine the underlying cause of the portal hypertension (fibrotic/inflammatory liver disease or PHPV).
- A hepatic biopsy should be performed in any case where surgical correction of a CPSS is pursued (to rule out concurrent parenchymal disease [inflammatory or fibrotic] or vascular disorder [PHPV]).
- Method of hepatic biopsy (percutaneous via ultrasonographic guidance, laparoscopic, or laparotomy) depends on many variables, including stability of patient,

Vascular disease

- With surgical attenuation of CPSS, portal hypertension and MAPSS may develop.
- Reevaluation via rectal or transplenic scintigraphy may be pursued in some cases after surgical attenuation to reassess the degree of shunting.
- Monitoring in medically managed vascular disorders (PHPV, MAPSS) is as for hepatobiliary disease. ■

See Aids & Resources, back page, for references, contacts, and appendices. Article archived on www.cliniciansbrief.com

Figure Credit

Adapted from *Veterinary Laboratory Medicine—Interpretation and Diagnosis*, 3rd ed. Meyer DJ, Harvey JW. Philadelphia: Saunders, 2004, with permission from Elsevier.

CPSS = congenital portosystemic shunt; MAPSS = multiple acquired portosystemic shunts; PHPV = primary hypoplasia of the portal vein; TSBA = total serum bile acids